

# CONTINUING EDUCATION

## EDUCATIONAL OBJECTIVES

After participating in this activity, clinicians should be better able to

- Differentiate the two types of vertebroplasties, percutaneous vertebroplasty and balloon kyphoplasty
- Describe the pathophysiology that leads to vertebral fractures in multiple myeloma
- Describe the risks and benefits of percutaneous vertebroplasty

### Disclosure of Conflicts of Interest

The Nurse Practitioner Healthcare Foundation (NPHF) assesses conflict of interest with its instructors, planners, reviewers, and other individuals who are in a position to control the content of CE activities. All relevant conflicts of interest that are identified are thoroughly vetted by NPHF for fair balance, scientific objectivity of studies utilized in this activity, and patient care recommendations. NPHF is committed to providing its learners with high quality CE activities and related materials that promote improvements or quality in health care.

The **faculty**: Jayne C. Kasian, BA, BN, CON(C), MN, and Laura Johnson, RN(NP), MN, reported no financial relationships or relationships to products or devices they or their spouse/life partner have with commercial interests related to the content of this CE activity.

The **planners, reviewers, and staff**: Fiona J. Shannon, MHS, FNP; Joyce Pagan; Kristen Childress, DNP, ARNP; Connie Morrison-Hoogstede, MN, ANP, AOCNP; and Genean M. Page, RN, OCN, reported no financial relationships or relationships to products or devices they or their spouse/life partner have with commercial interests related to the content of this CE activity.

### Disclaimer

The opinions expressed in the educational activity are those of the faculty and do not necessarily represent the views of or imply endorsement by Nurse Practitioner Healthcare Foundation, American Nurses Credentialing Center, or Haymarket Media Inc.

As this article contains only a review, participants have an implied responsibility to use this newly acquired information while also consulting other appropriate sources of information in order to gain full understanding of the topic.

## Vertebroplasty is effective for managing myelomatous VCFs

Jayne C. Kasian, BA, BN, CON(C), MN; Laura Johnson, RN(NP), MN

### STATEMENT OF NEED/PROGRAM OVERVIEW

Approximately 75% of patients with multiple myeloma will experience bone pain, and new vertebral fractures occur in approximately 15% to 30% of these patients. Nurses' interactions with patients from diagnosis through treatment make them the ideal person to recognize changes in a patient's functioning and to initiate interventions such as percutaneous vertebroplasty for vertebral compression fractures. The minimally invasive procedure is relatively low-risk but relies on careful patient selection based on nursing assessments. Nurse awareness of this treatment option and the patient selection criteria may be a significant factor in the use of percutaneous vertebroplasty to relieve patients' back pain and improve their quality of life.

### CE INFORMATION

**Title:** Vertebroplasty is effective for managing myelomatous VCFs

**Release date:** December 15, 2013

**Expiration date:** December 15, 2015

**Estimated time to complete this activity:** 36 minutes

Free continuing nursing education credit of 0.6 is available. After reading the article, go to [mycme.com](http://mycme.com) to register, take the posttest, and receive a certificate. A score of 80% is required to pass.

Please note that the posttest is available only on **myCME.com**.

The article may also be viewed at [OncologyNurseAdvisor.com](http://OncologyNurseAdvisor.com) and on the Nurse Practitioner Healthcare Foundation Web site: [www.nphealthcarefoundation.org](http://www.nphealthcarefoundation.org). For more information, contact Fiona Shannon at [fiona@nphealthcarefoundation.org](mailto:fiona@nphealthcarefoundation.org).

This continuing nursing education activity is provided by the Nurse Practitioner Healthcare Foundation (NPHF).

NPHF is accredited as a provider of continuing nursing education by the American Nurses Credentialing Center's Commission on Accreditation.

**Target audience:** This activity has been designed to meet the educational needs of registered nurses and nurse practitioners involved in the management of patients with cancer.

**Media:** Journal article and Web site ([myCME.com](http://myCME.com)); [OncologyNurseAdvisor.com](http://OncologyNurseAdvisor.com); [nphealthcarefoundation.org](http://nphealthcarefoundation.org))

**Co-provided by the Nurse Practitioner Healthcare Foundation and Haymarket Media Inc.**



# CONTINUING EDUCATION

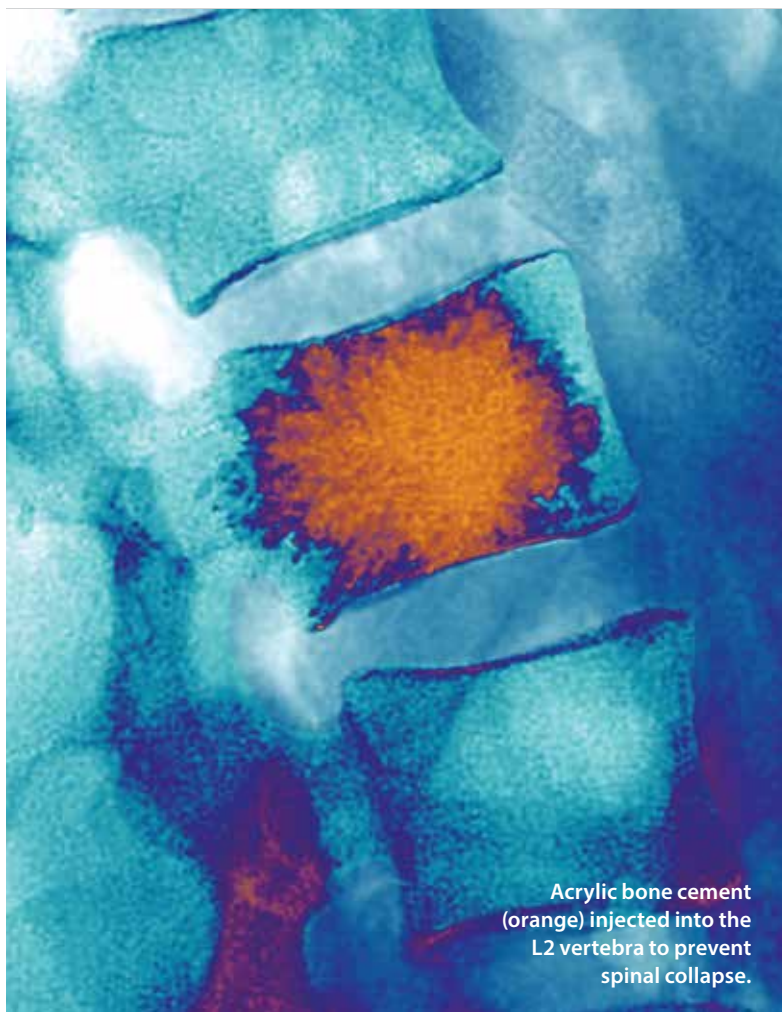
## EDUCATIONAL OBJECTIVES

After participating in this activity, clinicians should be better able to

- Differentiate the two types of vertebroplasties, percutaneous vertebroplasty and balloon kyphoplasty
- Describe the pathophysiology that leads to vertebral fractures in multiple myeloma
- Describe the risks and benefits of percutaneous vertebroplasty

# Vertebroplasty is effective for managing myelomatous VCFs

The minimally invasive procedure provides effective, immediate relief from the pain of vertebral compression fractures due to multiple myeloma.



Acrylic bone cement (orange) injected into the L2 vertebra to prevent spinal collapse.

JAYNE C. KASIAN, BA, BN, CON(C), MN;  
LAURA JOHNSON, RN(NP), MN

**M**ultiple myeloma is an incurable blood cancer of the plasma cells. However, the expansion of novel treatments has significantly prolonged overall survival to the extent that it can now be considered more of a chronic disease. During the illness trajectory, bone destruction is the most frequent cause of patient morbidity and mortality.<sup>1,2</sup> Symptomatically, bone involvement afflicts 70% to 100% of patients with myeloma and leads to distressing skeletal pain related to a variety of complications including pathological fractures, vertebral body collapses, and hypercalcemia.<sup>1-5</sup> The challenge is to effectively manage both bone pain and vertebral compression fractures (VCFs). This article reviews the role of vertebroplasty as an effective intervention in the treatment of symptomatic vertebral compression fractures in patients with multiple myeloma.

## MYELOMA BONE DISEASE

Multiple myeloma is a blood cancer that leads to the transformation of plasma cells, a type of

## TO TAKE THE POST-TEST FOR THIS CE ACTIVITY

and apply for 0.6 contact hours, please go to [myCME.com/CEDecember2013](http://myCME.com/CEDecember2013)

white blood cell located within the bone marrow, resulting in an overproduction of monoclonal immunoglobulins. These plasma cells proliferate at an unrestricted rate, overcrowding the marrow and diminishing the production of other normal cells. In healthy bones, bone remodeling is a seamless process whereby osteoclasts break down old or damaged bone, and osteoblasts lay down new bone. In patients with myeloma, malignant plasma cells within the bone marrow release cytokines that cause the surrounding bone to break down faster than it can be repaired. This process upsets bone metabolism by creating an imbalance between osteolytic and osteoblastic activity, which promotes the removal of compact bone.<sup>1,3</sup> This leads to a vicious cycle of perpetual bone loss accompanied by a spreading of myeloma plasma cells, and eventually bone destruction.<sup>3</sup> Patients with myeloma are then susceptible to both diffuse loss of bone mass, as well as the development of focal bone lytic lesions, which increase the risk of fracture. Of these skeletal-related complications, the vertebral bodies of the spine are the most likely to be affected by multiple myeloma.<sup>1,4,6</sup>

When myelomatous lytic lesions involve the vertebrae, vertebral stabilization is of utmost importance to prevent the sequelae of a compression fracture. Vertebral compression fractures are associated with unrelenting bone pain and resultant immobility. As a result, VCFs may severely diminish quality of life, compromise pulmonary function, increase the risk of developing deep vein thrombosis and pressure ulcers, interrupt sleep, increase fatigue, exacerbate emotional distress, produce analgesic-related constipation, and increase the risk of spinal cord compression.<sup>5,7</sup> In addition, VCFs may lead to the development of *kyphosis*, a spinal deformity. This particular deformity is associated with numerous complications including anorexia, due to compression of the abdominal contents; decreased activity tolerance, due to compromised lung capacity; and further spinal deformity, due to an altered center of gravity.<sup>4</sup>

## VERTEBRAL FRACTURE REPAIR

Vertebral pain is the most prevalent symptom of myelomatous bone disease. Systemic treatment of the disease itself is the most effective means of relieving vertebral pain, as it may slow the process of further bone destruction. Systemic treatment may be accompanied by various adjunctive interventions such as analgesic and bisphosphonate medications, targeted radiation, and open spinal surgery. These interventions are critical components of the treatment plan and may be indicated at some point in the disease trajectory. However, when used in isolation of other interventions, these treatments alone will not effectively restore the strength of collapsed vertebrae, nor will they provide immediate pain

relief. Satisfactory pain management and improved spinal integrity are best achieved through multidisciplinary collaboration. A relatively new and minimally invasive surgical procedure used to repair vertebral fractures is percutaneous vertebroplasty.

**Percutaneous vertebroplasty** is a minimally invasive vertebral augmentation procedure for the management of painful vertebral compression fractures. The successful use of this procedure was first documented in France in the mid-1980s, where it was used to treat painful vertebral collapses secondary to hemangiomas and osteoporosis.<sup>3,7</sup> Since then, the procedure has also shown promise for patients with painful myelomatous vertebral compression fractures. Percutaneous vertebroplasty is a relatively short procedure (15 to 20 minutes per vertebrae) with the aim to provide nearly immediate pain palliation as well as restoration of vertebral function.<sup>5,7</sup> The pain relief achieved through this procedure can improve functional abilities and enhance overall quality of life.<sup>1,3,7,8</sup> Most importantly, the rapid results of this procedure allow the continuation of systemic treatment, which is the key to controlling the progressive nature of multiple myeloma.<sup>7</sup>

## Vertebroplasty should be explored for myelomatous vertebral fractures associated with pain intractable to conservative management strategies.

The palliative vertebroplasty procedure is performed by an interventional radiologist, orthopedic surgeon, or neurosurgeon and is usually done under local anesthetic with the patient in the prone position.<sup>5,6</sup> In general, the portions of the spine that can be safely accessed via the percutaneous route are vertebrae T3 to L5. Experienced operators can safely perform this procedure up to the cervical area.<sup>4</sup> Once the targeted vertebrae are confirmed, a small cutaneous dorsal incision is required.<sup>2</sup> Under continuous fluoroscopic guidance, an 11- or 13-gauge trocar is placed in the damaged vertebral body via percutaneous extrapedicular or transpedicular approach.<sup>2,5-7</sup> The needle is advanced into the anterior third of the fractured vertebral body until it reaches midline.<sup>5</sup> At this position, a viscous cementlike mixture consisting of polymethylmethacrylate (PMMA) powder, barium sulfate powder, and an antibiotic powder for infection prophylaxis is then inserted into the vertebral body.<sup>5</sup> The PMMA functions to restore the compressive strength of the vertebrae

with the ultimate goal of alleviating intractable local pain and preventing a compression fracture.<sup>5</sup>

After the procedure, the incision is sutured, and the patient requires strict bed rest for 1 to 2 hours to allow cement polymerization.<sup>9</sup> Further imaging must be completed to identify postvertebroplasty artifacts before the patient can be discharged home. This postoperative CT scan is intended to rule out cement extravasation and becomes the new baseline for comparison with subsequent images.<sup>8</sup> The short procedure is typically a day surgery, with same-day discharge.

### Not all vertebral compression fractures are painful; therefore, other possible causes of the patient's pain must be explored.

**Balloon kyphoplasty** is a similar, newer procedure in which the spinal augmentation is achieved by first inflating a balloon inside the fractured vertebrae to create a void or cavity. The balloon is then deflated and removed, and PMMA is inserted into the newly created cavity of the affected vertebral body.<sup>5</sup> As with vertebroplasty, kyphoplasty can stabilize the vertebrae with the additional potential benefits of restoring vertebral height and correcting kyphosis. These advantages are coupled with a lower potential risk of cement extravasation compared with vertebroplasty.<sup>3</sup> Vertebroplasty typically requires a unipedicular approach, while kyphoplasty often requires a bipedicular approach using a larger specialized cannula.<sup>3</sup> As a result, kyphoplasty is a more expensive procedure.

Kyphoplasty is a more complex procedure, requires a longer time to complete, and patients may be more likely to need general anesthetic; therefore, vertebroplasty may be preferred in some cases. At present, well-conducted, randomized, controlled trials showing evidence that supports kyphoplasty as superior to vertebroplasty for either osteoporosis or tumor-related vertebral compression fractures is insufficient.<sup>10</sup> Efficacy of each procedure rests in the experience of the operator.

#### IDENTIFYING THE IDEAL CANDIDATES

Vertebroplasty should be explored for those patients with myelomatous vertebral fractures associated with well-localized, disabling pain intractable to conservative management strategies such as analgesic medications, bed rest, use of braces, and rehabilitation services. Suitable candidates

for the surgery will also have experienced both functional decline and diminished quality of life. The patient, caregiver, and members of the multidisciplinary team, including the oncology nurse, oncologist, radiologist, and spinal surgeon, must be involved in deciding whether or not a patient is a candidate for this procedure. A thorough assessment and consultation is required to identify those who will benefit from the intervention. Multiple factors are reviewed including clinical presentation, performance status, functional capacity, location of the fracture, extent of disease, and quality of life.<sup>5</sup>

The presence of localized pain is the most important indication for vertebroplasty; however, a clear correlation must be made between the patient's reports of pain and the level of fracture. Not all VCFs are painful; therefore, other possible causes of the patient's pain must be explored.<sup>4</sup> Additional indications for vertebroplasty include perioperative and postoperative surgical risks that preclude open spinal surgery.<sup>1,3,5-7</sup>

Contraindications for vertebroplasty include uncorrected coagulopathy, severe cardiopulmonary insufficiency, systemic or local infection at the site of planned injection, intolerance to prone positioning, spinal cord compression or symptomatic epidural compression of the neural elements, and allergy to procedure-related drugs and materials.<sup>4-7,9</sup> Prior to selection for the vertebroplasty procedure, each patient must undergo a preoperative work-up that includes, but is not limited to, a recent chest radiograph, an electrocardiogram (EKG), and baseline blood work including international normalized ratio (INR) to rule out coagulopathy.

After addressing these initial considerations, imaging studies are necessary to further determine candidacy and to rule out other causes of back pain.<sup>5</sup> Plain radiographs can be used to identify bone thinning, lytic lesions, and fractures. These radiographs are also necessary to ensure visualization of pedicles, to establish route of entry prior to fluoroscopy, and to ensure there is no evidence of osseous destruction, meaning that the dorsal vertebral wall is intact.<sup>7</sup> Further imaging is required to obtain a more detailed visualization of any damaged bone. Computed tomography (CT) scans help determine the exact location and severity of a fracture. In addition, CT scans can further reveal the extent of osseous destruction of the posterior vertebral cortex. Magnetic resonance imaging (MRI) has the advantage of showing the detail of the bone marrow and can evaluate for nerve root compression without exposing the patient to radiation. If the MRI reveals significant epidural soft tissue disease or cord compromise, consultation with radiation oncology is recommended prior to exploring vertebroplasty, as the mass size may need to be reduced through radiation treatment before vertebral augmentation.<sup>4,7</sup> In addition, if vertebral

lysis is evident, vertebroplasty may be used as an adjunct to radiation to prevent tumor growth.<sup>5</sup>

### POTENTIAL BENEFITS OF VERTEBROPLASTY

Percutaneous vertebroplasty is now considered a suitable therapeutic option for myelomatous vertebral compression fractures. The procedure is minimally invasive, well tolerated with low complication rates, and provides both immediate and long-lasting pain relief.<sup>1,3,5,6,9,11</sup> This procedure is preferred over other treatment options as it is usually performed under local anesthesia and allows for same-day discharge from hospital.<sup>2,3,7</sup> Successful spinal augmentation often improves patient mobility and decreases the need for analgesics thus avoiding the troublesome side effects of these medications.<sup>3,5,8</sup> A recent retrospective study of patients who had undergone vertebroplasty noted significant improvements in patients' reports of fatigue, depression, anxiety, drowsiness, and difficulty thinking as a result of spinal augmentation.<sup>11</sup>

The PMMA powder used in the procedure may have some antitumor effects that could produce additional long-lasting benefits for patients with multiple myeloma. Researchers

## The therapeutic relationship with your patient can facilitate early identification of changes in your patient's functional status.

hypothesize that this benefit may be related to cytotoxic and thermal effects that can destroy pain receptors and nerve endings in the affected vertebrae.<sup>3,5,7,8,10</sup> In addition, once PMMA is inserted into vertebrae, the space-occupying effect that occurs may also inhibit future growth of tumor cells.<sup>10</sup> Regardless if this holds true or not, vertebroplasty is associated with a wide range of benefits, most notably the rapid pain relief and increased performance status ensuring patients with multiple myeloma can continue their systemic treatment.

### POTENTIAL COMPLICATIONS OF VERTEBROPLASTY

Although vertebroplasty is known to be an effective treatment with a low complication rate, the procedure does have potential risks.<sup>6</sup> Most patients will experience some level of discomfort during administration of the local anesthetic. Additionally, as in any procedure in which the skin is penetrated, there is a potential risk of infection.<sup>8</sup>

The most serious perioperative risk is leakage of the cement out of the vertebral body through fracture fissures or vertebral

vein fissures.<sup>1,3,5,6,8,10</sup> This complication is more likely to occur when patients have myeloma with osteolytic destruction of cortical bone and disruption of the posterior wall.<sup>4,5</sup> The risk is further escalated when multilevel vertebroplasty is attempted and when the maximum of 4 cc of PMMA per vertebrae is exceeded.<sup>4,10</sup>

Cement leakage into the epidural space and perivertebral veins is usually asymptomatic but can lead to pulmonary embolism and neurologic problems such as myelopathy and radiculopathy.<sup>1,2</sup> A more serious problem may occur if the leakage is in a dangerous location such as the spinal canal, requiring emergent spine surgery to decompress the spinal canal.<sup>5</sup> The potential consequences of cement leakage must be weighed against the overall benefit intended to be achieved by percutaneous vertebroplasty in patients with multiple myeloma.

### IMPLICATIONS FOR NURSING PRACTICE

The therapeutic relationship with your patient can facilitate early identification of changes in a patient's functional status that may be secondary to significant new or progressive back pain. Nurses can initiate discussions with members of the health care team regarding the change in patient status and the possible role of percutaneous vertebroplasty in a patient's care plan. When a consensus that the patient is an appropriate candidate for vertebroplasty is reached, patient education about the goals of treatment, the potential risks and benefits, and the procedure itself is a critical first step.

The results of the pain assessment and the imaging studies are included in the consultation process with the oncology, radiology, and neurosurgery departments. A formal referral, which includes all vertebral imaging results, is sent to an interventional radiologist, who can assist in identifying vertebrae that may be amendable to treatment.<sup>8</sup>

Nurse assessment of potential candidates' initial (baseline) pain should be performed using a validated pain inventory; this same inventory should then be used in the postprocedure and follow-up assessments to ensure consistency. A visual analogue scale (VAS) of pain is one of the most common inventories used among patients with myeloma. However, it is not inclusive of the other symptoms and disabilities experienced by patients with myelomatous VCFs. The Roland-Morris Disability Questionnaire is a more reliable outcome measure for evaluating the preoperative status and the postoperative efficacy of vertebroplasty.<sup>9,11,12</sup> This tool is easily accessible (available online), simple to administer, well-validated, specific to back pain, and appropriate for assessing vertebroplasty outcomes.<sup>12</sup>

Because the pain relief from vertebroplasty can be sustained for 6 months or longer, the outcome assessment should be

The procedure is known to provide rapid pain relief, decrease disability, and significantly improve patients' quality of life.

used at baseline, and repeated at 1 week, 1 month, 6 months, and 1 year postoperatively.<sup>9</sup> This pre- and postoperative comparison documents the outcome of vertebroplasty for pain relief and improved quality of life.

Appropriate aftercare of the patient includes nursing-directed health teaching, particularly with respect to the increase in mobility that is expected with optimized pain control. Patients should be encouraged to resume activity as tolerated, but to avoid heavy lifting for at least 6 weeks. A timely referral to physiotherapy is indicated for guidance regarding gentle exercise in the postoperative period.<sup>4</sup>

CONCLUSION

Since its inception in the 1980s, percutaneous vertebroplasty has proven to be a safe, effective, and durable treatment for the pain associated with vertebral compression fractures.<sup>3</sup> Among patients with vertebral fractures secondary to multiple myeloma, vertebroplasty is an important adjunct to other standard treatments such as analgesic medications, systemic treatments, and radiation therapy.<sup>5</sup> The procedure is known to provide rapid pain relief, decrease disability, and significantly improve patients' quality of life. Therefore, all affected patients should be assessed as potential candidates for vertebroplasty.

Members of the nursing profession are an integral part of the patient care team as both advocates and assessors of patient status particularly in patients with multiple myeloma and painful malignant vertebral compression fractures. Their contribution can ensure patients receive the most effective treatments. ■

**Acknowledgment** The authors dedicate this article to the respectful memory of Dr. Ade Olujuhunge and his compassionate care for patients with multiple myeloma. They also thank Ruth Holmberg, librarian at CancerCare Manitoba, for her assistance with the literature search for this article.

**Jayne Kasian** is a nurse practitioner at CancerCare Manitoba, in Winnipeg, Manitoba, Canada. **Laura Johnson** is a nurse practitioner in the emergency department at Health Sciences Centre, and an instructor at the University of Manitoba in Winnipeg, Manitoba, Canada, in the Nurse Practitioner program.

REFERENCES

1. La Maida GA, Giarratana LS, Acerbi A, et al. Cement leakage: safety of minimally invasive surgical techniques in the treatment of multiple myeloma vertebral lesions. *Eur Spine J.* 2012;21(suppl 1):S61-S68. doi:10.1007/s00586-012-2221-3.
2. Masala S, Anselmetti GC, Marcia S, et al. Percutaneous vertebroplasty in multiple myeloma vertebral involvement. *J Spinal Disord Tech.* 2008;21(5):344-348. doi:10.1097/BSD.0b013e3181454630.
3. Anselmetti GC, Manca A, Montemurro F, et al. Percutaneous vertebroplasty in multiple myeloma: prospective long-term follow-up in 106 consecutive patients. *Cardiovasc Intervent Radiol.* 2012;35(1):139-145. doi:10.1007/s00270-011-0111-4.
4. Hussein MA, Vrionis FD, Alison R, et al; International Myeloma Working Group. The role of vertebral augmentation in multiple myeloma: International Myeloma Working Group Consensus Statement. *Leukemia.* 2008;22(8):1479-1484. doi:10.1038/leu.2008.127.
5. Wu AS, Fourney DR. Supportive care aspects of vertebroplasty in patients with cancer. *Support Cancer Ther.* 2005;2(2):98-104. doi:10.3816/SCT.2005.n.003.
6. Tancioni F, Lorenzetti M, Navarra P, et al. Vertebroplasty for pain relief and spinal stabilization in multiple myeloma. *Neurol Sci.* 2010;31(2):151-157. doi:10.1007/s10072-009-0197-5.
7. Chen LH, Hsieh MK, Niu CC, et al. Percutaneous vertebroplasty for pathological vertebral compression fractures secondary to multiple myeloma. *Arch Orthop Trauma Surg.* 2012;132(6):759-764. doi:10.1007/s00402-012-1474-y.
8. Garland P, Gishen P, Rahemtulla A. Percutaneous vertebroplasty to treat painful myelomatous vertebral deposits—long-term efficacy outcomes. *Ann Hematol.* 2011;90(1):95-100. doi:10.1007/s00277-010-1021-2.
9. Chew C, Ritchie M, O'Dwyer PJ, Edwards R. A prospective study of percutaneous vertebroplasty in patients with myeloma and spinal metastases. *Clin Radiol.* 2011;66(12):1193-1196. doi:10.1016/j.crad.2011.08.004.
10. Chew C, Craig L, Edwards R, et al. Safety and efficacy of percutaneous vertebroplasty in malignancy: a systematic review. *Clin Radiol.* 2011;66(1):63-72. doi:10.1016/j.crad.2010.09.011.
11. Mendoza TR, Koyyalagunta D, Burton AW, et al. Changes in pain and other symptoms in patients with painful multiple myeloma-related vertebral fracture treated with kyphoplasty or vertebroplasty. *J Pain.* 2012;13(6):564-570. doi:10.1016/j.pain.2012.03.003.
12. Trout AT, Kallmes DF, Gray LA, et al. Evaluation of vertebroplasty with a validated outcome measure: the Roland-Morris Disability Questionnaire. *AJNR Am J Neuroradiol.* 2005;26(10):2652-2657. http://www.ajnr.org/cgi/pmllookup?view=long&pmid=16286418. Accessed November 6, 2013.

TO TAKE THE POST-TEST FOR THIS CE ACTIVITY and apply for 0.6 contact hours, please go to [myCME.com/CEDecember2013](http://myCME.com/CEDecember2013)